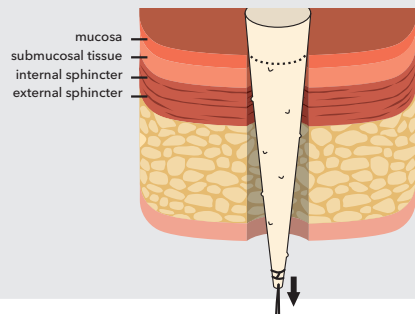
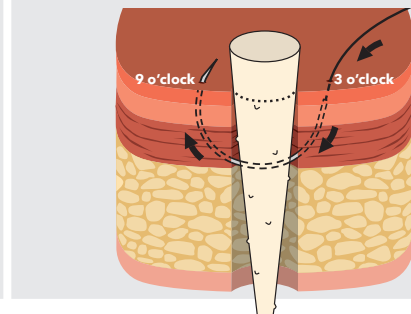


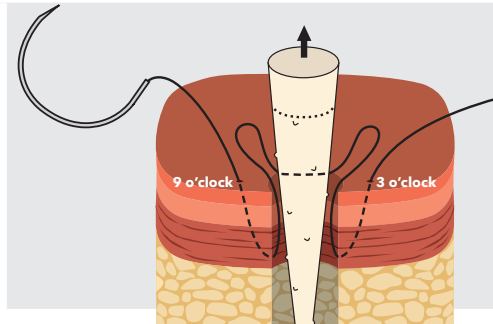
Blind pass anal fistula suture technique



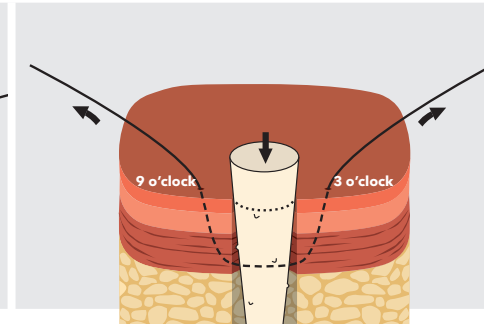
1 Pull the fistula plug, narrow end first, through the internal opening of the fistula until you feel a slight resistance.



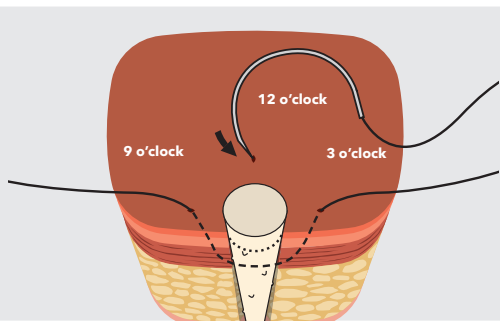
2 Adjacent to the internal opening, pass a suture deep to the internal sphincter layer and directly through the center of plug, exiting on the opposite side. Imagine the area of the internal opening as a clock face; the suture should enter at 3 o'clock and exit at 9 o'clock.



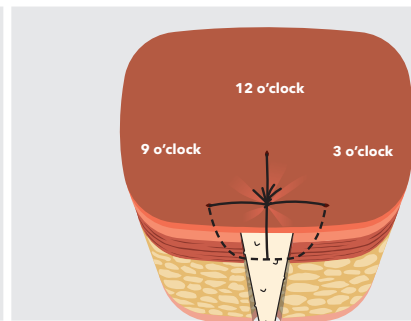
3 Gently pull the plug partially out of the internal opening to verify that the suture went directly through center of the plug.



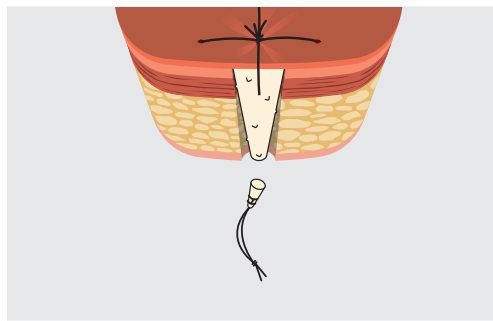
4 Pull the plug back into its original position as in step 1. Remove the needle from the suture. Pull the suture from both ends to remove any slack from the fistula tract.



5 Repeat steps 2-4, making a stitch perpendicular to the first (from 12 o'clock to 6 o'clock).



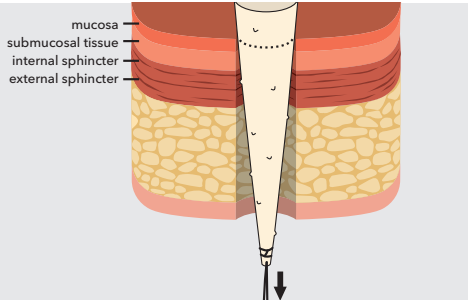
6 Trim the plug so that it is level with mucosa, then tie off the sutures over the top of the plug, effectively pulling the mucosal layer over the top of the plug. No part of the plug should be visible at the internal opening.



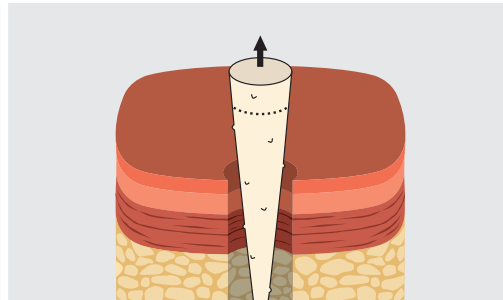
7 Trim the external end of plug flush with the skin. **Do not** suture closed the external opening of the fistula tract. Slightly enlarge the external opening to facilitate drainage.

The techniques presented in this guide are recommendations that should help you achieve optimum results, but this guide is not meant to be a substitute for the package insert.

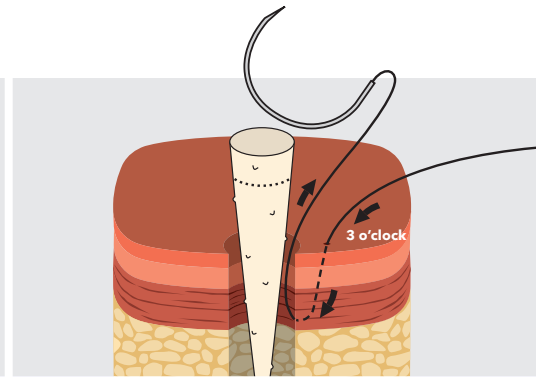
Direct visualization anal fistula suture technique



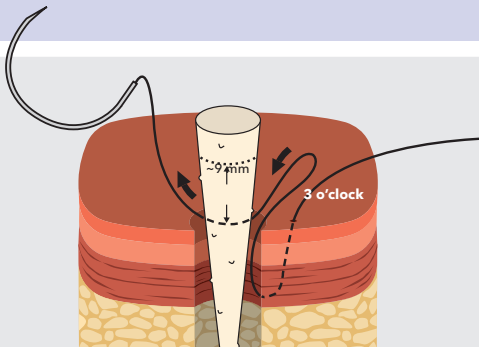
1 Pull the fistula plug, narrow end first, through the internal opening of the fistula until you feel a slight resistance. Note where the plug will need to be trimmed in step 7.



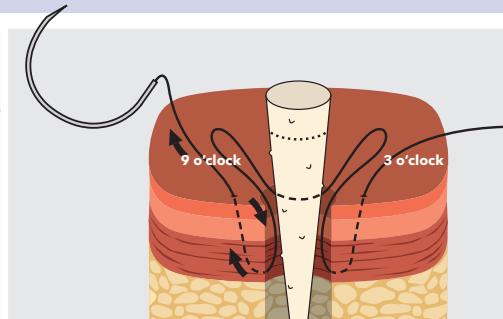
2 Gently pull the plug partially out of the internal opening.



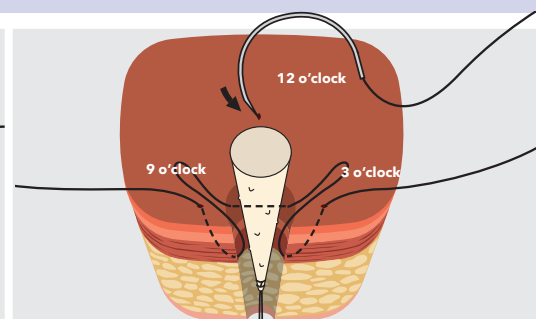
3 Adjacent to the internal opening, pass a suture deep to the internal sphincter layer and back out of the internal opening **without** piercing the plug. Imagine the area of the internal opening as a clock face; the suture should enter at 3 o'clock.



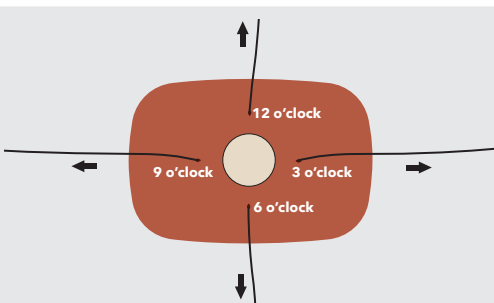
4 Continue this stitch by passing the needle directly through the center of plug approximately 9 mm below the trim line noted in step 1.



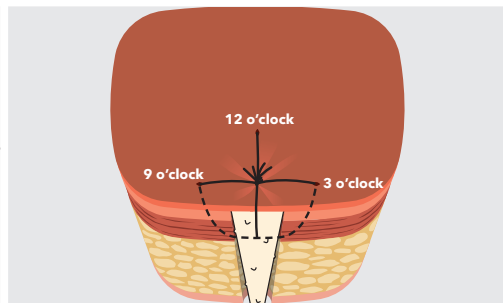
5 Continue the stitch by passing the needle down alongside the plug, deep to the internal sphincter layer, and back out at 9 o'clock.



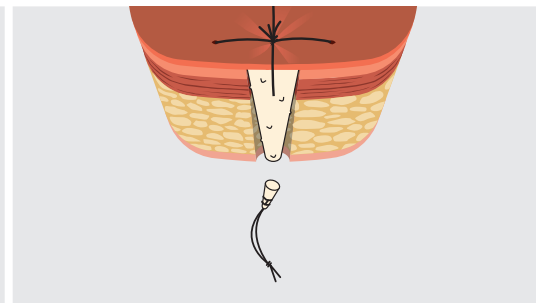
6 Repeat steps 3-5, making a stitch perpendicular to the first (from 12 o'clock to 6 o'clock).



7 Pull the plug back into its original position as in step 1. Pull the ends of the sutures to remove any slack from the fistula tract. Trim the plug level with mucosa.



8 Tie off the sutures over the top of the plug, effectively pulling the mucosal layer over the top of plug. No part of the plug should be visible at the internal opening.



9 Trim the external end of the plug flush with the skin. **Do not** suture closed the external opening of the fistula tract. Slightly enlarge the external opening to facilitate drainage.